PI-RADS v2.1

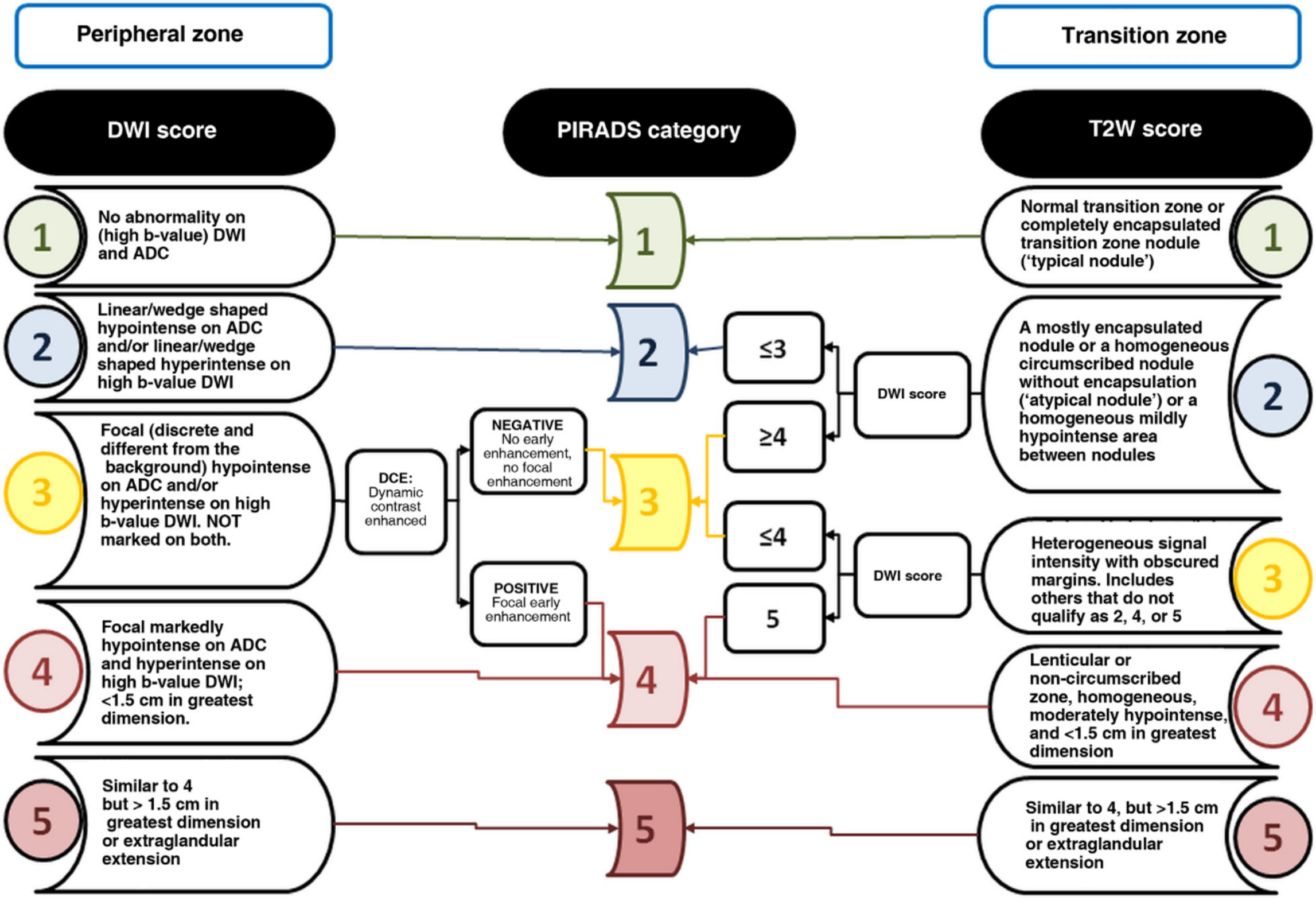
Peripheral zone
Transition zone
DWI score
PIRADS category
T2W score
1
No abnormality on (high b-value) DWI and ADC
1
Normal transition zone or completely encapsulated transition zone nodule ('typical nodule')
1
2
Linear/wedge shaped hypointense on ADC and/or linear/wedge shaped hyperintense on high b-value DWI
2
≤3
DWI score
A mostly encapsulated nodule or a homogeneous circumscribed nodule without encapsulation ('atypical nodule') or a homogeneous mildly hypointense area between nodules
2
3
Focal (discrete and different from the background) hypointense on ADC and/or hyperintense on high b-value DWI. NOT marked on both.
DCE: Dynamic contrast enhanced
NEGATIVE No early enhancement, no focal enhancement
POSITIVE Focal early enhancement
3
≥4
≤4
5
DWI score
Heterogeneous signal intensity with obscured margins. Includes others that do not qualify as 2, 4, or 5
3
4
Focal markedly hypointense on ADC and hyperintense on high b-value DWI; <1.5 cm in greatest dimension.
4
Lenticular or non-circumscribed zone, homogeneous, moderately hypointense, and <1.5 cm in greatest dimension
4
5
Similar to 4 but > 1.5 cm in greatest dimension or extraglandular extension
5
Similar to 4, but >1.5 cm in greatest dimension or extraglandular extension
5