

# School of MRI 2023: VI-RADS

## VI-RADS SCORING SYSTEM

### Assessment for T2W imaging

3.2.4.2. *Assessment for T2W imaging.* Muscle appears hypointense on T2W images. This should be the first MR appearance to search in the examination. Interruption of the low SI muscular line may suggest muscle invasion. Different scenarios may be present [48,49,53]:

1. Structural category (SC) 1: uninterrupted low SI line representing the integrity of muscularis propria (lesion <1 cm; exophytic tumor with or without stalk and/or thickened inner layer)
2. SC 2: uninterrupted low SI line representing the integrity of muscularis propria (lesion >1 cm; exophytic tumor with stalk and/or high SI thickened inner layer, when present, or sessile/broad-based tumor with high SI thickened inner layer, when present)
3. SC 3: lack of category 2 findings with associated presence of an exophytic tumor without stalk, or sessile/broad-based tumor without high SI thickened inner layer but with no clear disruption of low SI muscularis propria
4. SC 4: interruption of low SI line suggesting extension of the intermediate SI tumor tissue to muscularis propria
5. SC 5: extension of intermediate SI tumor to extravesical fat, representing the invasion of the entire bladder wall and extravesical tissues

### Assessment for DWI imaging

3.2.4.4. *Assessment for DWI/ADC.* The tumor is hyperintense on DWI and hypointense on ADC map. Muscularis propria may present intermediate SI, while the stalk and inner layer have low SI on DWI [51,53]:

1. DW category 1: muscularis propria with intermediate continuous SI on DWI (lesion <1 cm, hyperintense on DWI and hypointense on ADC, with or without stalk and/or low SI thickened inner layer on DWI)
2. DW category 2: muscularis propria with continuous intermediate SI on DWI (lesion >1 cm, hyperintense on DWI and hypointense on ADC, with low SI stalk and/or low SI thickened inner layer on DWI, or broad-based/sessile tumor with low/intermediate SI thickened inner layer on DWI)
3. DW category 3: lack of category 2 findings (lesions corresponding to T2 category 3 findings) but with no clear disruption of low SI muscularis propria.
4. DW category 4: High SI tumor on DWI and low SI tumor on ADC extending focally to muscularis propria.
5. DW category 5: High SI tumor on DWI and low SI tumor on ADC extending to the entire bladder wall and extravesical fat.

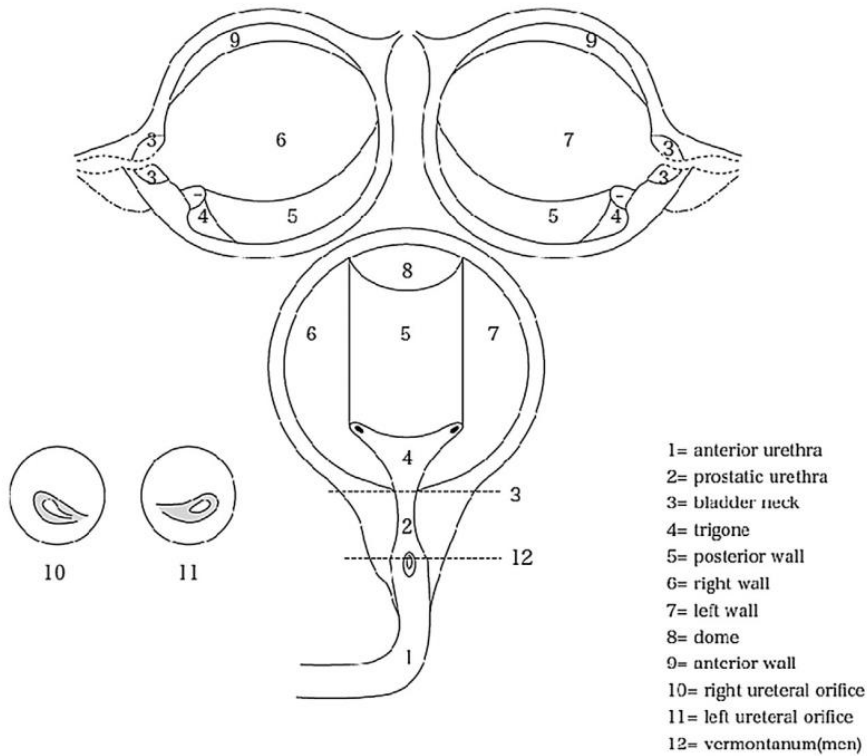
### Assessment for DCE MRI

3.2.4.3. *Assessment for DCE MRI.* As for DCE MRI, tumor and inner layer enhance early and may enhance at the same time and grade. Muscularis propria should maintain no enhancement in the early phase, and it is recognizable as a low SI line under the tumor [44,46,48,51]. Contrast-enhanced (CE) categories are as follows:

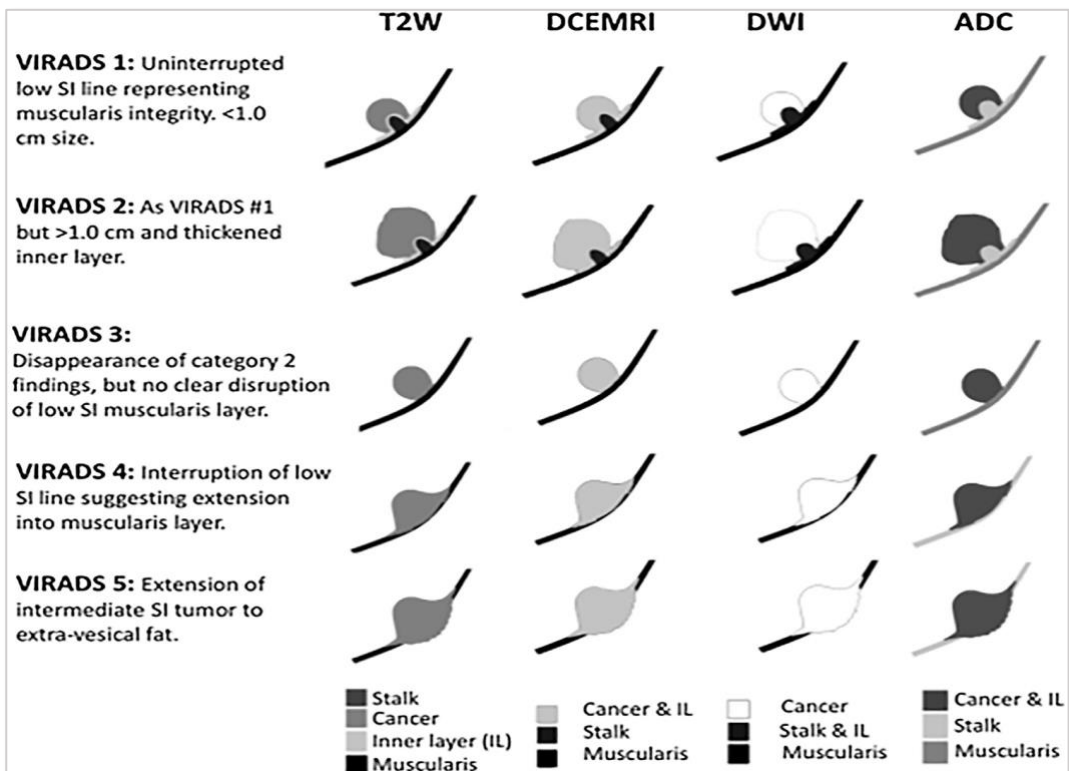
1. CE category 1: No early enhancement of the muscularis propria (lesions corresponding to SC 1 findings)
2. CE category 2: no early enhancement of muscularis propria with early enhancement of inner layer (lesions corresponding to SC 2 findings)
3. CE category 3: lack of category 2 findings (lesions corresponding to SC category 3 findings) but with no clear disruption of low SI muscularis propria
4. CE category 4: tumor early enhancement extends focally to muscularis propria
5. CE category 5: tumor early enhancement extends to the entire bladder wall and to extravesical fat

# School of MRI 2023: VI-RADS

## BLADDER MAP

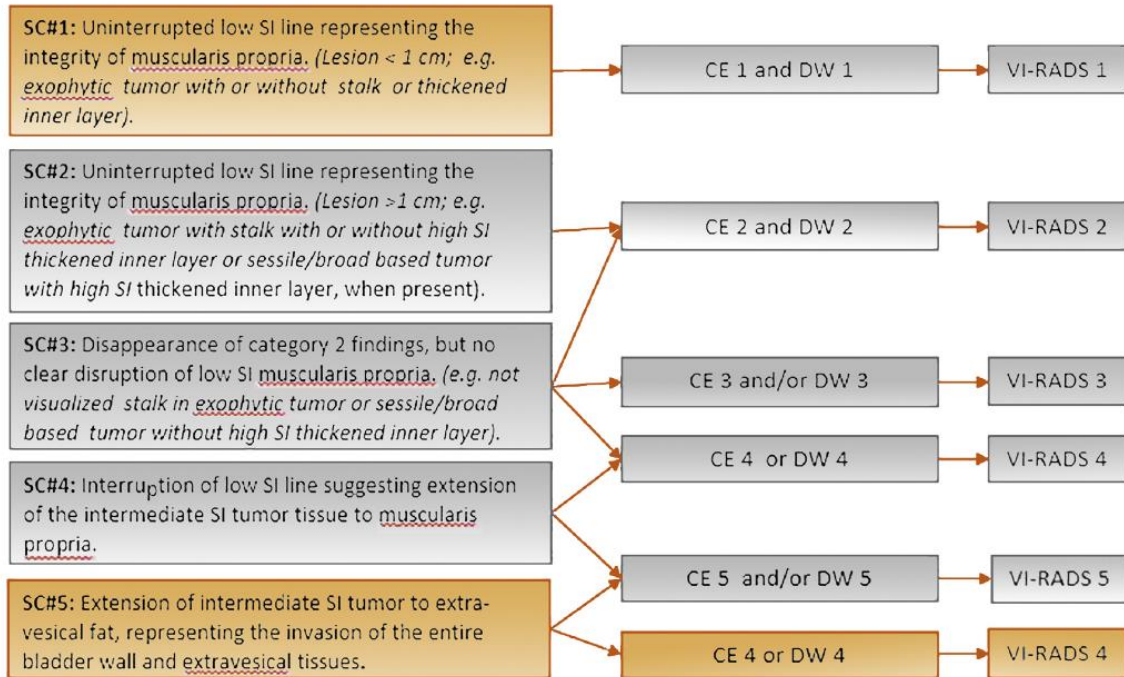


## VI-RADS SCHEMATIC REPRESENTATION



# School of MRI 2023: VI-RADS

## VI-RADS ALGORITHM



## Notes

.....

.....

.....

.....

.....

.....